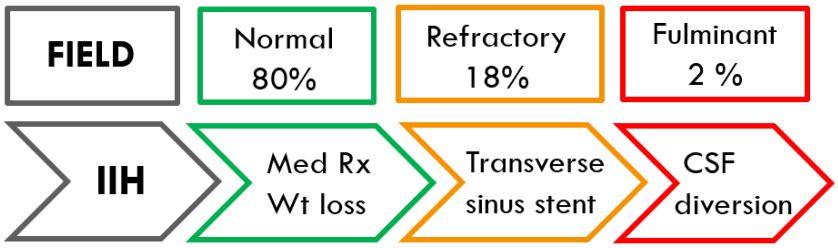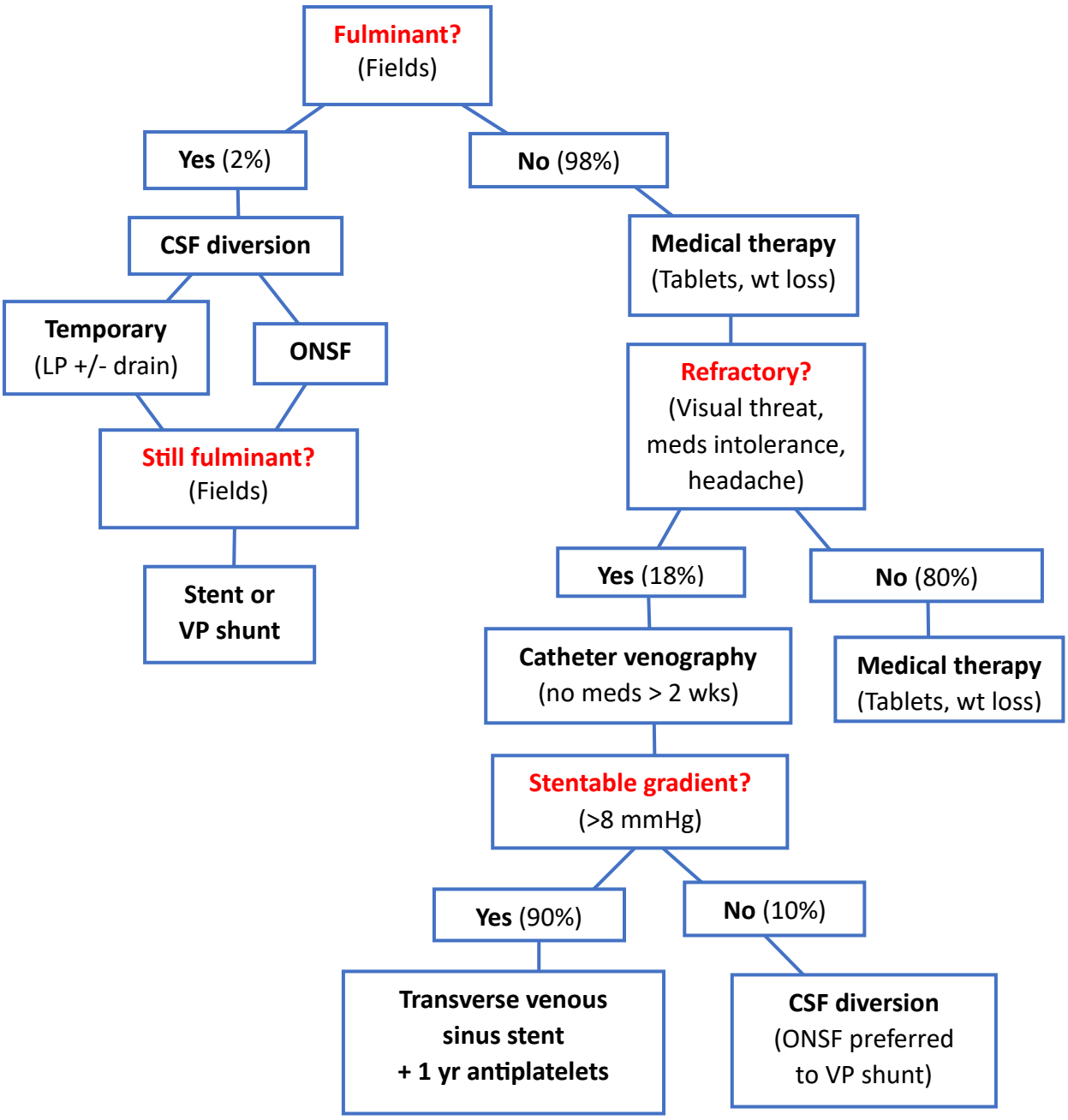Transverse Sinus Stenting Reverses Medically Refractory Idiopathic Intracranial Hypertension